

# Adenoid Cystic Carcinoma of the Breast: A Rare Salivary Gland-Type Tumor with Favorable Prognosis

© Cenk Yazkan<sup>1</sup>, © Elvin Tanriverdi<sup>1</sup>, © Funda Dinç<sup>2</sup>, © Leyla Tekin<sup>3</sup>

<sup>1</sup>Muğla Sıtkı Koçman University Faculty of Medicine, Department of General Surgery, Muğla, Turkey

<sup>2</sup>Muğla Sıtkı Koçman University, Faculty of Medicine, Department of Radiology, Muğla, Turkey

<sup>3</sup>Muğla Sıtkı Koçman University, Faculty of Medicine, Department of Pathology, Muğla, Turkey

## ABSTRACT

Adenoid cystic carcinoma (ACC) of the breast is an exceptionally rare malignancy, accounting for less than 0.1% of all breast cancers. Despite being a subtype of triple-negative breast carcinoma, ACC demonstrates a markedly favorable prognosis, with low rates of axillary lymph node involvement and distant metastasis. Histologically, the tumor is characterized by a dual cell population arranged in cribriform, tubular, or solid patterns. In this report, we present the case of a 65-year-old woman who detected a palpable mass in the upper outer quadrant of her left breast during self-examination. Imaging studies revealed a hypoechoic, spiculated lesion, which was subsequently classified as breast imaging-reporting and data system 4C. Core needle biopsy confirmed the diagnosis of ACC, with immunohistochemistry demonstrating estrogen receptor-negative, progesterone receptor-negative, human epidermal growth factor receptor2-negative status, and positive staining for (sex-determining region y)-related high mobility group -box 10 and cluster of differentiation 117. The patient underwent breast-conserving surgery with sentinel lymph node biopsy, revealing negative nodal involvement. Histopathological examination confirmed ACC with 70% cribriform and 30% solid components, without perineural or lymphovascular invasion. Postoperative management included adjuvant radiotherapy (60 Gy) without chemotherapy. At 12 months post-treatment, no evidence of recurrence was observed. This case highlights the importance of accurate histological and immunohistochemical assessment in establishing the diagnosis and guiding treatment. Given its rarity and generally indolent course, awareness of ACC among clinicians and pathologists is essential to avoid overtreatment and to ensure appropriate surgical and radiotherapeutic management.

**Keywords:** Adenoid cystic carcinoma, Triple-negative breast cancer, Salivary gland-type tumor, Breast-conserving surgery, Sentinel lymph node biopsy, Immunohistochemistry

## INTRODUCTION

Adenoid cystic carcinoma (ACC) is a rare malignant tumor that often involves the salivary gland. Its overall incidence rate is approximately 0.1%. The majority of the cases are female patients aged 50-60 years [1,2]. Its most frequent clinical presentation is a painless palpable mass. It has a highly favorable prognosis, despite being triple negative. Ten-year survival rates range between 85% and 100%. The probability of metastasis to the axilla is extremely low [3-5]. Histologically, it has a dual pattern that consists of myoepithelial cells surrounding pseudocysts and epithelial cells surrounding true glands. Morphologically, it may be solid, cribriform, tubular, or trabecular [2,3,6]. As it is rarely observed, explicit criteria regarding optimal treatment have yet to be established. However, surgery is the most

common treatment method implemented in clinical practice [6]. This paper aims to present and discuss ACC of the breast, a very rare breast carcinoma, to raise awareness of this clinical entity.

## CASE REPORT

A 65-year-old female patient presented with a lump in the left breast that was detected during a self-breast examination. In the patient's physical examination, a 2 cm hard fixed mass was detected at the outer and upper quadrant of the left breast. No pathological findings were observed in the axillary examination. On mammogram an irregular mass with indistinct margins was detected on the upper outer quadrant of left breast (Figure 1). The breast ultrasonography revealed



**Address for Correspondence:** Elvin Tanriverdi MD, Muğla Sıtkı Koçman University Faculty of Medicine, Department of General Surgery, Muğla, Turkey

**E-mail:** elvintanriverdi.dr@gmail.com **ORCID ID:** orcid.org/0000-0002-2375-7140

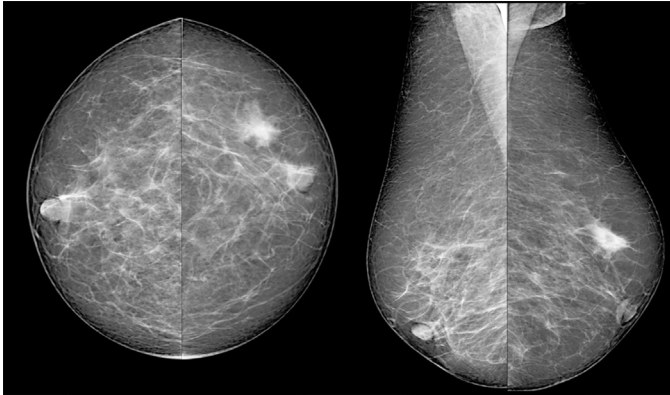
**Received:** 03.04.2025 **Accepted:** 22.08.2025 **Publication Date:** 29.08.2025

**Cite this article as:** Yazkan C, Tanriverdi E, Dinç F, Tekin L. Adenoid cystic carcinoma of the breast: a rare salivary gland-type tumor with favorable prognosis. J Cau Med Sci. 2025;3(3):21-25



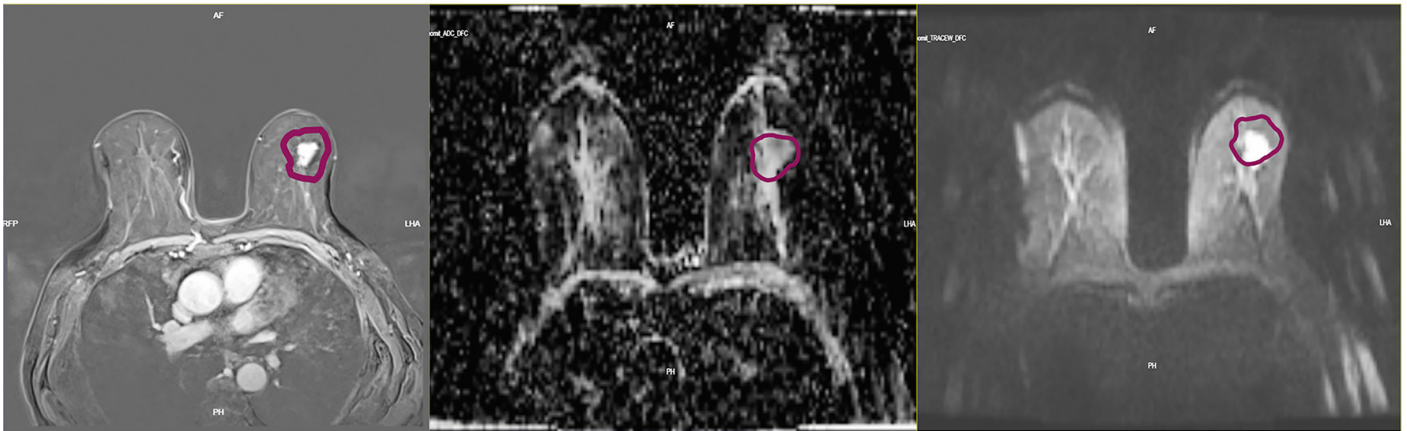
Copyright© 2025 The Author. Published by Galenos Publishing House on behalf of Azerbaijan Gastroenterology and Invasive Endoscopy Society. This is an open access article under the Creative Commons Attribution-Attribution-NonCommercial 4.0 (CC BY-NC 4.0) International License.

a hypoechoic heterogeneous spiculated mass with posterior acoustic shadowing measuring 17×10 mm in diameter. The lesion was evaluated as breast imaging-reporting and data

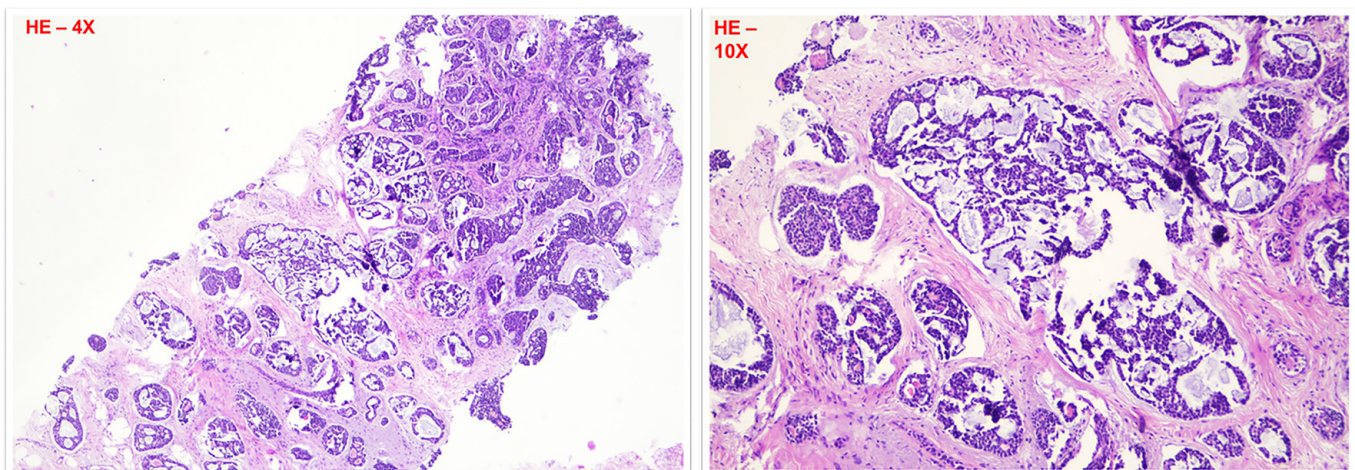


**Figure 1.** Bilateral mammography shows an irregular mass with indistinct margins in the upper outer quadrant of left breast

system (BI-RADS) 4C, due to American College of Radiology -BI-RADS lexicon. Also, magnetic resonance imaging (MRI) was performed and showed an irregular mass, with homogeneous progressive enhancement on post-contrast images and diffusion-weighted imaging (Figure 2). There were no additional remarkable findings on MRI. Ultrasound-guided percutaneous core biopsy was performed. Biopsy revealed a tumor consisting of both solid and cribriform patterns (Figure 3). The immunohistochemical evaluation was reported as estrogen receptor (ER) negative, progesterone receptor (PR) negative, human epidermal growth factor receptor 2 (HER2) negative, Ki-67 (5%). P63 myoepithelial cells were detected as positive in cells with pseudolumen (Figures 4,5). Staining for (sex-determining region y)-related high mobility group -box 10 (SOX10) was expressed as positive in both myoepithelial-like cells and luminal-like cells, while cluster of differentiation 117 (CD117) was expressed as positive in only luminal-like cells (Figure 6).



**Figure 2.** Breast magnetic resonance images demon strates an irregular mass, hyperintense on T2-weighted with homogeneous progressive enhancement on post contrast images and diffusion restriction on diffusion weighted imaging



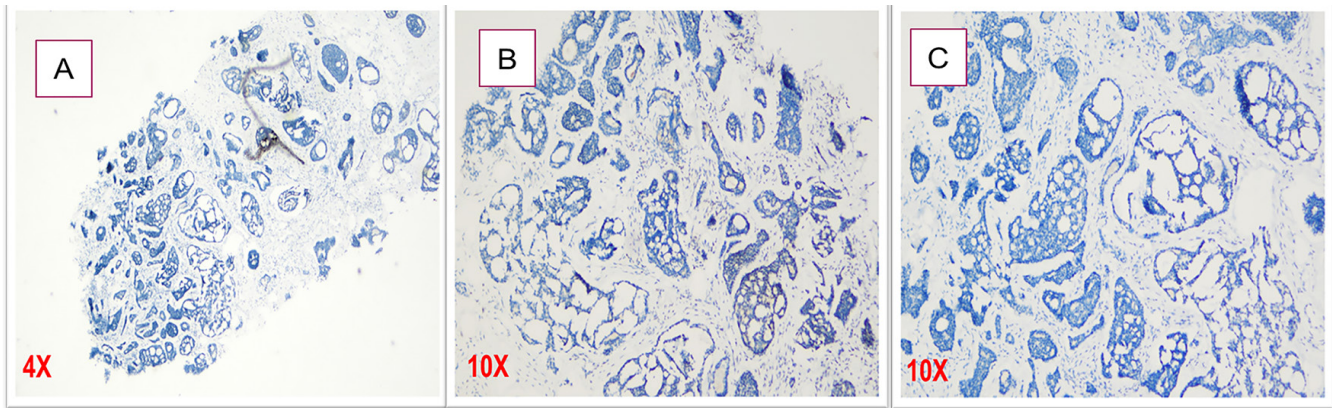
**Figure 3.** A tumor consisting of both solid and cribriform patterns



The patient underwent breast-conserving surgery with sentinel lymph node biopsy. In frozen evaluation, three sentinel lymph nodes were reported as reactive, and surgical margins were negative. According to the histopathological evaluation, the excision material was reported to be a salivary gland type breast tumor [ER, PR, Cellular erb-B2 (CerbB2) (-), Ki-67: %10(+), SOX10(+), CD117(+), p40(+), 70% cribriform, 30% solid, a tumor diameter of 2.7×2.5×2 cm, without perineural

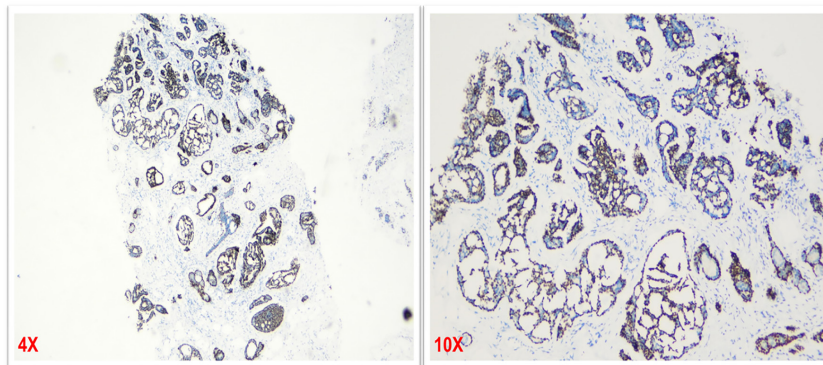
and lymphovascular invasion (-), T2N0, ACC]. Postoperative management consisted of adjuvant radiotherapy (60 Gy). Chemotherapy was not administered, in accordance with the known low-risk biological behavior of ACC.

At 12-month follow-up, the patient remains disease-free with no signs of local or distant recurrence. Good functional and cosmetic results were obtained.

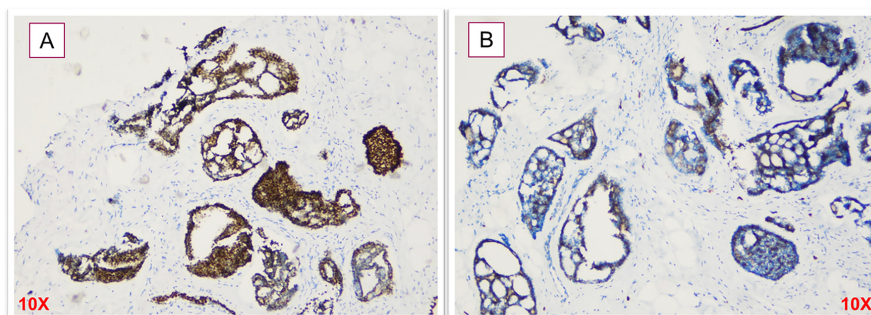


**Figure 4.** Results of immunohistochemical evaluation [A: ER(-), B: PR(-), C: CerbB2/HER2(-)]

ER: Estrogen receptor, PR: Progesterone receptor negative, HER2: Human epidermal growth factor receptor 2, CerbB2: Cellular erb-B2



**Figure 5.** P63 myoepithelial, detected as (+) in cells with pseudolumen



**Figure 6.** Immunohistochemical stains [A: SOX10 (+), B: CD117 (+)]

SOX10: Staining for (sex-determining region y)-related high mobility group -box 10, CD117: Cluster of differentiation 117

## DISCUSSION

ACC is a rare breast tumor that most commonly occurs in patients aged 50-60 years. These patients often present with a painless palpable mass [1-6]. ACC can be detected in various organs such as the salivary glands, cervix, larynx, skin, and lungs [7]. However, the breast stands out because it is among the locations where an occurrence is rarely seen. Mass size usually varies between 1 and 8 cm (mean 3 cm). It is often located in the breast at the periareolar region and upper outer quadrant [3,8]. Our case showed similarities to the data in the literature in that the patient was aged 65 years, and presented with a palpable mass. The tumor was located at the intersection of the retroareolar region and the upper outer quadrant. Cases often exhibit a basal-like phenotype with negative immunohistochemical stains for ER, PR, and HER2. Though it is triple-negative, it has lower rates of distant metastasis, nodal involvement, and local recurrence when totally excised, and thus it differs from other triple-negative breast tumors. Histological variants: Classical variant: The most frequent variant combines three different architectural models (cribriform, tubular, or solid) ranging from low to high nuclear grade. Solid-basaloid variant: It has solid nests, a high mitotic rate, necrosis, Ki67>30%, and a more aggressive clinical course [9,10]. The pathological staging of the tumor is performed based on its solid components. Cases without solid components are classified as stage 1, those with solid components <30% of all tumor areas are classified as stage 2, and those with solid components >30% of all tumor areas are classified as stage 3 [10]. The high pathological stage increases the likelihood of recurrence and distant metastasis and indicates a worse prognosis. In our case, a 70% cribriform and a 30% solid pattern were observed. The gold standard in the treatment is surgery.

Breast-conserving surgery and mastectomy can be preferred as surgical methods due to patients' requests, and lesion features as well. In a 14-patient case series in which long-term survival rates of patients were examined, 10 patients underwent a mastectomy, and three patients underwent breast-conserving surgery. In a similar study in which seven patients were examined, five patients underwent mastectomy, and one patient underwent breast-conserving surgery [6,10]. Triple-negative breast cancers are aggressive types of breast cancer characterized by a poor prognosis and insensitive to hormone therapies due to negative hormone receptors. The preferred treatment method is surgery combined with adjuvant chemotherapy. However, although most ACC cases are triple negative, they have a good prognosis due to their low probability of lymph node involvement and distant metastasis, slow progression, and favorable differentiation in their histological appearance.

ACC of the breast, despite its triple-negative phenotype, exhibits distinct biological behavior with generally favorable outcomes and low responsiveness to chemotherapy. Current literature suggests that adjuvant chemotherapy is not routinely recommended due to the low rates of lymph node involvement and distant metastasis [4,6]. Complete surgical excision with negative margins, often combined with radiotherapy, has been shown to provide excellent local control, reducing the necessity for systemic therapy [5]. In our case, the decision to forgo chemotherapy was based on favorable prognostic features, including complete tumor resection, absence of lymphovascular invasion, and a low proliferative index (Ki-67: 10%). This approach aligns with the indolent nature of ACC and aims to avoid unnecessary treatment-related toxicity while maintaining optimal oncological outcomes.

Although ACC is triple-negative, its clinical behavior contrasts sharply with other triple-negative breast cancers, such as basal-like carcinoma, which are typically aggressive and have a poorer prognosis. This distinction underscores the importance of accurate histological diagnosis to avoid unnecessary aggressive treatments.

## CONCLUSION

This case highlights the necessity of a multidisciplinary approach to diagnose and manage rare breast tumors like ACC. Pathologists play a pivotal role in distinguishing ACC from other triple-negative cancers, ensuring patients receive tailored treatments without overtreatment.

### Ethics

**Informed Consent:** The patient's written consent was obtained for the writing and publication of her case, including the publication of images.

### Footnotes

### Authorship Contributions

Surgical and Medical Practices: C.Y., E.T., F.D., L.T., Concept: C.Y., E.T., F.D., L.T., Design: C.Y., E.T., F.D., L.T., Data Collection or Processing: C.Y., E.T., F.D., L.T., Analysis or Interpretation: C.Y., E.T., F.D., L.T., Literature Search: C.Y., E.T., F.D., L.T., Writing: C.Y., E.T.

**Conflict of Interest:** No conflict of interest was declared by the authors.

**Financial Disclosure:** The authors declared that this study received no financial support.

## References

1. Thomas DN, Asarian A, Xiao P. Adenoid cystic carcinoma of the breast. J Surg Case Rep. 2019;2019:rjy355.

2. Miyai K, Schwartz MR, Divatia MK, Anton RC, Park YW, et al. Adenoid cystic carcinoma of breast: recent advances. *World J Clin Cases*. 2014;2:732-41.
3. Kashiwagi S, Asano Y, Ishihara S, Morisaki T, Takashima T, et al. Adenoid cystic carcinoma of the breast: a case report. *Case Rep Oncol*. 2019;12:698-703.
4. Ghabach B, Anderson WF, Curtis RE, Huycke MM, Lavigne JA, et al. Adenoid cystic carcinoma of the breast in the United States (1977 to 2006): a population-based cohort study. *Breast Cancer Res*. 2010;12:R54.
5. Kim M, Lee DW, Im J, Suh KJ, Keam B, et al. Adenoid cystic carcinoma of the breast: a case series of six patients and literature review. *Cancer Res Treat*. 2014;46:93-7.
6. Zhang W, Fang Y, Zhang Z, Wang J. Management of adenoid cystic carcinoma of the breast: a single-institution study. *Front Oncol*. 2021;11:621012.
7. Glazebrook KN, Reynolds C, Smith RL, Gimenez EI, Boughey JC. Adenoid cystic carcinoma of the breast. *AJR Am J Roentgenol*. 2010;194:1391-6.
8. Pia-Foschini M, Reis-Filho JS, Eusebi V, Lakhani SR. Salivary gland-like tumours of the breast: surgical and molecular pathology. *J Clin Pathol*. 2003;56:497-506.
9. Emerick C, Mariano FV, Vargas PA, Nör JE, Squarize CH, et al. Adenoid cystic carcinoma from the salivary and lacrimal glands and the breast: different clinical outcomes to the same tumor. *Crit Rev Oncol Hematol*. 2022;179:103792.
10. Foschini MP, Chillotti S, Ciudino R, Fabbri VP, Righi A, et al. Morphological spectrum of adenoid-cystic carcinoma of the breast: focus on diagnostic and prognostic features. *Diagn Histopathol*. 2022;28:142